

# Clinical Application of Serum Eye Drops for Herpetic Keratitis in Cats: A Pilot Study.

Se Eun Kim, D.V.M., Ph.D.<sup>1</sup>

Mi-Kyung Lee, D.V.M.<sup>2</sup>

Kangmoon Seo, D.V.M., M.S., Ph.D.<sup>3</sup>

<sup>1</sup>Department of Veterinary Surgery and Ophthalmology, Haemaru Referral Animal Hospital, 8-6, 319 Hwangsaetul-ro, Bundang-gu, Seongnam-si, Kyeonggi-do 13590, Republic of Korea.

<sup>2</sup>Irion Animal Hospital, 445 Dosandaero, Gangnam-gu, Seoul 06015, Republic of Korea

<sup>3</sup>Department of Veterinary ophthalmology, College of Veterinary Medicine, Seoul National University, 1 Gwanak-ro, Gwanak-gu, Seoul 08826, Republic of Korea

Corresponding author:

Se Eun Kim, D.V.M., Ph.D.

Department of Veterinary Surgery and Ophthalmology, Haemaru Referral Animal Hospital, 8-6, 319 Hwangsaetul-ro, Bundang-gu, Seongnam-si, Kyeonggi-do 13590, Republic of Korea.  
Tel: +82-31-781-2992  
Fax: +82-31-781-2993  
E-mail: chubbyfox@gmail.com

**KEY WORDS:**feline, herpetic keratitis, serum, allogeneic, autologous, cornea, cat.

## ABSTRACT

This study was performed to identify the clinical effect of using serum eye drops as an adjuvant treatment for herpetic keratitis in cats. We reviewed the medical records of seven cats (9 eyes) that were diagnosed with herpetic keratitis based on the clinical features and history. All cases showed recurrent or unresponsive corneal ulcers that had not healed after 3 weeks with conventional treatment. Thus they received supplementary treatment with serum eye drops. We also assessed the correlations between the defect duration prior to serum administration and the duration to healing after the serum treatment. The mean age of the cats was  $1.43 \pm 2.26$  years. The cats received various treatments including topical antibiotics ( $n = 9$ ),

antivirals ( $n = 8$ ), non-steroidal anti-inflammatory eye drops ( $n = 2$ ), and artificial tears ( $n = 2$ ). The mean duration from ulcerative keratitis onset to serum administration was  $24.78 \pm 7.16$  days. All cases were completely healed without ulcer relapse for 3 months. The mean duration to healing was  $19.33 \pm 2.26$  days, and the duration from ulcerative keratitis onset to serum administration was significantly correlated with the duration to healing after the treatment ( $r_2 = 0.895$ ,  $P < 0.01$ ). Our results showed that the serum eye drops were effective as an adjuvant treatment for herpetic keratitis in cats that were unresponsive to conventional treatments, particularly in cats with recent ulcers.

## INTRODUCTION

Pre-corneal tear film covers the corneal and conjunctival surfaces and protects the underlying structures. Tears also play an important

role in corneal immunity since they contain numerous nutrients and immune mediators.<sup>1</sup> However, various ocular surface disorders such as keratitis, including herpetic keratitis, can disrupt tear production. With this development, serum eye drops are often used as a treatment in humans.<sup>2-8</sup>

The composition of tears and serum eye drops are similar in terms of their ingredients.<sup>9</sup> Autologous serum contains numerous beneficial ingredients, including vitamin A, lysozyme, epidermal growth factor, fibronectin, and transforming growth factor beta, all of which are important for corneal and conjunctival integrity.<sup>9</sup> Theoretically, fresh autologous serum is the most appropriate option for treating keratitis and herpetic keratitis.

A study on human patients with keratoconjunctivitis sicca (KCS) showed that treatment with autologous serum led to significant improvements in the tear film breakup times, corneal vital staining, pain scores, and impression cytology.<sup>6</sup> Another more recent study showed that autologous serum eye drops were an effective treatment for patients with persistent corneal epithelial defects (PED), including patients with neurotrophic keratopathy, a degenerative corneal disease that develops owing to a viral infection of the trigeminal nerve or its branches.<sup>10</sup> However, the use of autologous serum is contraindicated in infants and the elderly, as well as in patients with severe systemic disease, obesity, chronic illnesses, or those with a fear of blood collection. In these cases, allogeneic serum eye drops obtained from healthy relatives are used. Allogeneic serum from a blood bank has also been utilized to treat patients with severe corneal disease and was reportedly as effective for PEDs, including neurotrophic keratitis, as autologous serum.<sup>11,12</sup>

In small animal medicine, autologous serum eye drops have been usually used to manage severe corneal ulcerative disease, including “melting ulcers,” especially in dogs.<sup>13</sup> In cats, the main cause of conjunctivitis is feline herpes virus-1 (FHV-1), with

the second most common ocular manifestation being keratitis. Conventional treatment options for feline herpetic keratitis include topical and systemic antivirals and oral L-lysine.<sup>14</sup> Unfortunately, the corneal ulcers secondary to FHV-1 can become indolent ulcers or chronic stromal keratitis, even with these antiviral therapies in some cases. Stromal keratitis accompanied deep vessel injection and inflammatory cell infiltration, and the healing may be delayed in these corneal lesions.

Since the pathogenesis and clinical signs of feline herpetic keratitis are similar to those of neurotrophic keratopathy in human beings, it is possible that the efficacy of serum eye drops shown in people may also extend to cats, though this remains to be investigated. Therefore, this pilot study was performed to identify the efficacy of serum eye drops as an adjuvant treatment for herpetic keratitis in cats.

## **MATERIALS AND METHODS**

### **Patients**

We reviewed the medical records of seven cats (9 eyes) that had recurrent herpetic keratitis or herpetic keratitis that was unresponsive to conventional therapy. All cats had corneal ulcers that had not healed after 3 weeks of conventional therapy with topical antibiotics and/or antivirals. The feline herpes virus infections were diagnosed according to the clinical signs and through PCR analyses performed using samples obtained from the eye or nasal discharge.

### **Serum Preparation and Administration**

We collected 6 mL of blood from the jugular vein of each included cat or donor cat, and placed it directly into a serum separating tube (Vacutainer® SST™ II, BD, Plymouth, UK) containing clot activator. The sample was clotted for 20 min at room temperature and centrifuged at 3,000 rpm for 10 min to obtain the serum. The un-diluted serum was immediately placed into a 5 mL sterile eye-drop bottle and kept refrigerated under 4°C. The serum eye drops were topically administered to each cat six times a day, and the

**Table 1.** Serum type and previous medications

Cat	Eye	Breed	Age	Serum type	Previous medications	
					Topical	
1	OD	DSH	4 months	Allogeneic	Ab, Av	
1	OS	DSH	4 months	Allogeneic	Ab, Av	
2	OS	Turkish Angora	7 months	Allogeneic	Ab, At	Systemic Av
3	OD	DSH	4 months	Allogeneic	Ab, Av	
3	OS	DSH	4 months	Allogeneic	Ab, Av	
4	OD	DSH	3 years	Autologous	Ab, Av, NS	
5	OD	DSH	4 months	Allogeneic	Ab, Av	
6	OD	DSH	7 years	Autologous	Ab, Av, NS, At	
7	OS	DSH	4 months	Allogeneic	Ab, Av	

DSH = domestic shorthair; Ab = antibiotics; Av = antivirals; At = artificial tears; NS = Non-steroidal anti-inflammatory drugs

previous medications were continued.

### Evaluations

To evaluate the effects of the serum eye drops, the pre-serum period and therapeutic period were calculated. The pre-serum period was defined as the duration from ulcerative keratitis onset to the beginning of serum administration. The therapeutic period was defined as the duration to corneal ulcer healing after serum administration.

### Statistical Analysis

The age distribution, pre-serum periods, and therapeutic periods are expressed as the mean  $\pm$  SD. Statistical analyses were performed using SPSS 21.0 (SPSS Inc., Chicago, IL, USA). To evaluate the correlation between the pre-serum period and therapeutic period, linear regression analysis was employed. The data within 95% confidence level were considered statistically significant.

### RESULTS

Six domestic short hair cats and one Turkish Angora cat were included in this study. Of these, five cats were <1 year old and the other two cats were 3 and 7 years old. Two cats of the <1 year old had ulcers on

both eyes. The mean age was  $1.40 \pm 2.28$  years. The five younger cats (<1 year) were administered allogeneic serum, while the two older cats were treated with autologous serum.

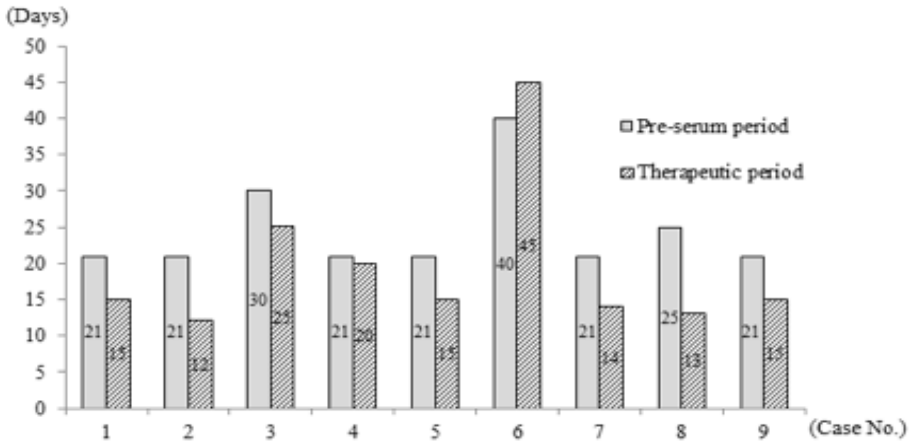
Before serum administration, all eyes were treated with topical antibiotics to prevent secondary bacterial infection. We administered topical antivirals to eight eyes in six cats and administered oral antivirals to the eye of one cat. Two eyes, each in a separate cat, were treated with topical non-steroidal anti-inflammatory drugs. Additionally, artificial tears were used to treat two eyes in two separate cats (Table 1).

The pre-serum period ranged from 21 to 40 days, with a mean of  $24.78 \pm 7.16$  days. The therapeutic period ranged from 12 to 45 days, with a mean of  $19.33 \pm 2.16$  days (Figure 1). The pre-serum period and therapeutic period in the same eye showed a proportional correlation ( $r^2=0.895$ ,  $P<0.01$ , Figure 2).

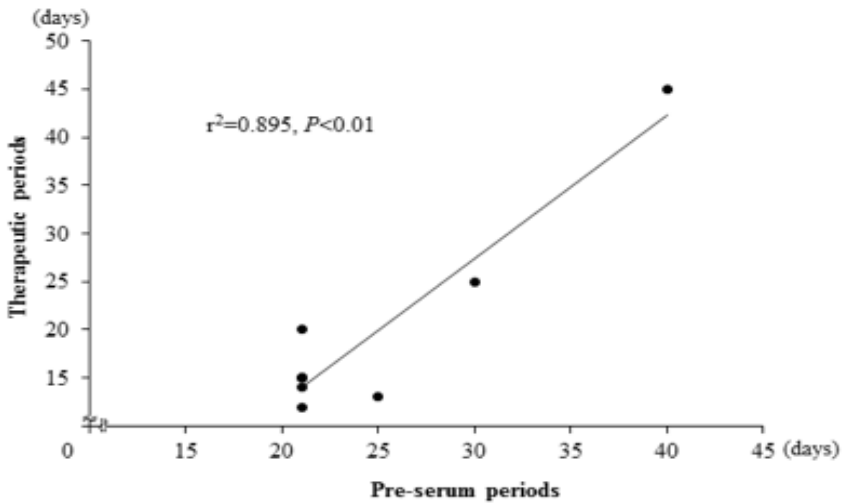
### DISCUSSION

In the present study, a proportional correlation was demonstrated between the pre-serum period and therapeutic period. It was thought that these chronic types of kerati-

**Figure 1.** Pre-serum period and therapeutic period of each cat. The mean pre-serum period and therapeutic period were  $24.78 \pm 7.16$  days and  $19.33 \pm 2.16$  days, respectively.



**Figure 2.** Linear regression analysis between the pre-serum period and therapeutic period. The pre-serum period and therapeutic period in the same eye showed a proportional correlation.



tis in this study generally showed delayed recovery compared to simple and recent corneal ulcers, although the serum eye drop was administered. These findings implied that the serum eye drops were more effective at the early stage of herpetic keratitis.

Generally, cats are more stressed by restraint than are human beings or dogs, and the systemic clinical signs of the herpesvirus could be concurred or worsened by stress. Furthermore, it is difficult to collect enough blood from kittens to administration of the serum eye drops. In these cases, allogeneic serum should be applied for the treatment of feline herpetic keratitis. The present study showed allogeneic serum effectively healed the corneas of young cats with herpetic keratitis.

A limitation of our study was that the allogeneic serums were not tested for the titers of the herpes virus or its antibody. However, the allogeneic serum donors were clinically normal and had no infectious diseases. For safety purposes, further studies should be performed on antigen testing (eg, with PCR) before applying the allogeneic serums.

The present study revealed that serum eye drops were an effective adjuvant treatment in cats with herpetic keratitis that was unresponsive to conventional treatments. Additionally, the therapeutic period for serum eye drops was proportional to the pre-serum period. These findings suggest that serum eye drops should be applied to cats in the early stage of herpetic keratitis for a good prognosis.

### Conflict of Interest

The authors declared no potential conflicts of interest with respect to the research, authorship and/or publication of this article.

### REFERENCES

1. Giuliano EA. Diseases and surgery of the canine lacrimal secretory system. In: Gelatt KN, Gilger BC and Kern TJ (eds), *Veterinary ophthalmology*. 5th ed. Ames: Wiley-Blackwell, 2013, pp 912-944.
2. Fox RI, Chan R, Michelson JB, et al. Beneficial effect of artificial tears made with autologous serum in patients with keratoconjunctivitis sicca. *Arthritis Rheum* 1984; 27: 459-461.

3. Geerling G, MacLennan S and Hartwig D. Autologous serum eye drops for ocular surface disorders. *Br J Ophthalmol* 2004; 88: 1467-1474.
4. Kojima T, Ishida R, Dogru M, et al. The effect of autologous serum eye drops in the treatment of severe dry eye disease: a prospective randomized case-control study. *Am J Ophthalmol* 2005; 139: 242-246.
5. Kojima T, Higuchi A, Goto E, et al. Autologous serum eye drops in the treatment of dry eye diseases. *Cornea* 2008; 27: S25-S30.
6. Noble BA, Loh RS, MacLennan S, et al. Comparison of autologous serum eye drops with conventional therapy in a randomised controlled crossover trial for ocular surface disease. *Br J Ophthalmol* 2004; 88: 647-652.
7. Tsubota J, Goto E, Fujita H, et al. Treatment of dry eye by autologous serum application in Sjögren's syndrome. *Br J Ophthalmol*. 1999; 83: 390-395.
8. Young AL, Cheng AC, Ng HK, et al. The use of autologous serum tears in persistent corneal epithelial defects. *Eye* 2004; 18: 609-614.
9. Tsubota K, Higuchi A. Serum application for the treatment of ocular surface disorders. *Int Ophthalmol Clin* 2000; 40: 113-122.
10. Jeng BH and Dupps WJ Jr. Autologous serum 50% eyedrops in the treatment of persistent corneal epithelial defects. *Cornea* 2009; 28: 1104-1108.
11. Chiang CC, Lin JM, Chen WL, et al. Allogeneic serum eye drops for the treatment of severe dry eye in patients with chronic graft-versus-host disease. *Cornea* 2007; 26: 861-863.
12. Chiang CC, Lin JM, Chen WL, et al. Allogeneic serum eye drops for the treatment of persistent corneal epithelial defect. *Eye*. 2009;23: 290-3.
13. Herring IP. Clinical pharmacology and therapeutics. Part 4: Mydriatics /cycloplegics, anesthetics and tear substitutes and stimulators. In: Gelatt KN, Gilger BC and Kern TJ (eds), *Veterinary ophthalmology*. 5th ed. Ames: Wiley-Blackwell, 2013, pp 423-434.
14. Stiles J. Feline ophthalmology. In: Gelatt KN, Gilger BC and Kern TJ (eds), *Veterinary ophthalmology*. 5th ed. Ames: Wiley-Blackwell, 2013, pp 1477-1559.