

Unraveling a Commercial Formula to Relieve Halitosis in Dogs

Sergio Canello¹

Gianandrea Guidetti²

Alessandro Di Cerbo^{3*}

Antonio Scarano³

Raffaella Cocco⁴

¹Forza10 USA Corp., Research and Development Department, 10142 Canopy Tree Ct. 32836 Orlando (FL); Tel. +1 (407) 530-6303, E-mail. sergio@forza10usa.com

²SANYpet S.p.a., Research and Development Department, Via Austria 3, Bagnoli di Sopra, 35023 Padua, Italy; Tel. +390429785401, E-mail. gianandrea@forza10.com

³Department of Medical, Oral and Biotechnological Sciences, Dental School, University G. d'Annunzio of Chieti-Pescara, Chieti, Italy; E-mail Alessandro811@hotmail.it, ascarano@unich.it,

⁴Department of Veterinary Medicine, Pathology and Veterinary Clinic Section, University of Sassari, Sassari, Italy. E-mail: rafco@uniss.it

(*) Corresponding author: Alessandro Di Cerbo, Department of Medical, Oral and Biotechnological Sciences, Dental School, University G. D'Annunzio of Chieti-Pescara, Chieti, Italy; E-mail. alessandro811@hotmail.it; Ph. +393923731318

KEY WORDS: Halitosis, clinical evaluation, nutraceutical diet, oxytetracycline

ABSTRACT

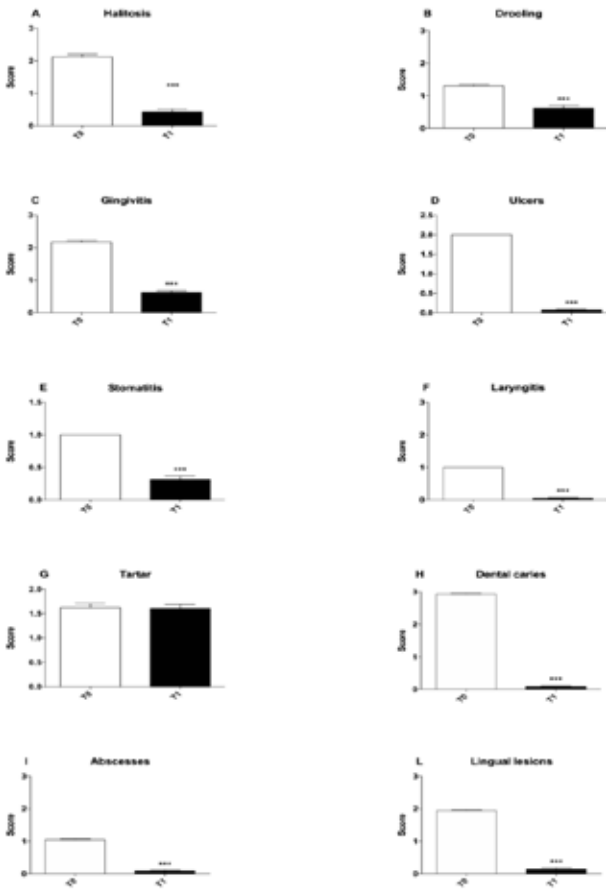
Halitosis represents a cause of social problems despite of the availability of commercial aids to counteract it. A dietary approach represents an innovative solution. The aim of this clinical evaluation was to assess the efficacy of a commercially available nutraceutical diet in a cohort of dogs suffering from chronic halitosis and manifesting at least one symptom among drooling, gingivitis, ulcers, stomatitis, laryngitis, tartar, dental caries, abscess, lingual lesions. Dogs were fed the nutraceutical diet over a period of 30 days, receiving a veterinary inspec-

tion before and at the end of the evaluation. Most of symptoms resulted in significant improvement at the end of the evaluation period. We hypothesize that halitosis may be a consequence of a daily intake of food contaminated with oxytetracycline.

INTRODUCTION

Halitosis, produced by gram-negative bacteria present within the mouth, is considered a cause of social problems.¹ Amino acids, the main energy source of such bacteria, are responsible for the production of some volatile sulphur compounds (i.e. methyl mercaptan, hydrogen sulfide and dimethyl sulfide). As a consequence of a high protein intake, dogs and cats can easily develop halitosis. Clinical studies also revealed that dogs and

Figure 1. Graphical representations of score trend of each symptom before (T0) and after 30 days of evaluation (T2). (A) halitosis; (B) drooling; (C) gingivitis; (D) ulcers; (E) stomatitis; (F) laryngitis; (G) tartar; (H) dental caries; (I) abscesses; (L) lingual lesions, *** $p < 0.001$.



cats can develop plaque deposits on the teeth and tongue, representing another source of oral malodor and even periodontal disease.²⁻⁴ According to literature reports, oral malodor and periodontal disease result from a 2-stage process that begins with microbial biofilm accumulation and flows into an inflammatory reaction.

However, as a matter of fact, daily tooth brushing, which is considered the most reliable approach to remove plaque and in turn reduce the onset of gingivitis, periodontal disease, and oral malodor,⁵ is accomplished only by approximately 2% of pet owners.⁶

Many effective aids have been proposed and commercialized to counteract halitosis and dental plaque formation such as chews,⁷ treats,⁸ drink solutions,⁹ and topical gels.¹⁰ However, a dietary approach to fulfil both daily nutritional requirements and improve halitosis could represent an innovative solution for “lazy” but careful pet owners.

The diet used in this clinical evaluation consisted in a mixed formula of fish proteins and rice carbohydrates enriched with *Ribes nigrum*, *Salvia officinalis L*, *Thymus L*, egg white lysozyme, propolis, bioflavonoids, and vitamin C. Literature reports highlighted the *in vitro* antibacterial activity exerted by *Ribes nigrum* (blackcurrant) juice on bacterial strains associated with gingival inflammation, oral malodour, and dental caries formation.¹¹⁻¹² An antimicrobial activity was also observed for *Salvia officinalis L* (Sage) that, in a tablet formulation with Lavender and Mastic or

zinc gluconate, also significantly reduced volatile sulphide compound (methylmercaptan and hydrogen sulphide) levels.^{13,14}

On the other hand, *Salvia officinalis L* has been also used for the treatment of ulcers and inflammation.¹⁵ As to bioflavonoids and vitamin C, they have shown anti-inflammatory and bacteriostatic activity, while propolis, rich in flavonoids endowed with antibacterial, antifungal, antiviral, antioxidant, and anti-inflammatory properties, is used for plaque control, oral lesions treat-

ment, intracanal medicaments, and wound healing.¹⁶⁻¹⁸

The aim of this clinical evaluation was to assess the efficacy of a commercially available nutraceutical diet in a cohort of dogs suffering from chronic halitosis and manifesting at least one symptom among drooling, gingivitis, ulcers, stomatitis, laryngitis, tartar, dental caries, abscess, or lingual lesions.

MATERIALS AND METHODS

One hundred four dogs of different breeds (mean age \pm SEM; 6.8 ± 0.3 years and mean weight \pm SEM; 31.22 ± 0.6 Kg; 68 males, 36 females) suffering from chronic halitosis and manifesting at least one symptom among drooling, gingivitis, ulcers, stomatitis, laryngitis, tartar, dental caries, abscess, and lingual lesions were enrolled in this clinical evaluation. Dogs were fed a commercially available nutraceutical diet over a period of 30 days.

Operative procedures and animal care were performed in according to national and international regulations (Italian regulation D. Lgs. 116/1992 and European Union regulation 86/609/EC). ARRIVE guidelines in animal research were also consulted and considered.¹⁹

The Diet

The diet was industrially prepared according to recommendations of Nutritional Guidelines established by The European Pet Food Industry Federation. It was composed of dry kibbles and heart-shaped tablets composed of 60-80% hydrolyzed proteins and 20-40% minerals added to titrated and standardized nutraceutical substances (*Ribes nigrum* 0.0040%, *Salvia officinalis* L 0.0087%, *Thymus* L 0.0127%, egg white lysozyme 0.0078%, propolis 0.0161%, bioflavonoids 0.0077%, and vitamin C 0.025%).

Symptoms Evaluation

All dogs received veterinary inspections before and at the end of the evaluation. Halitosis, drooling, gingivitis, ulcers, stomatitis, laryngitis, tartar, dental caries, abscess, and lingual lesions were graded by a well-trained

vet according to the following score: 0 = absent, 1 = tolerable, 2 = moderate, 3 = marked.

Statistical Analysis

Data were analyzed using Prism 6 (Graph-Pad software, Inc., San Diego, USA). All data are presented as the means \pm standard error of the mean and were first checked for normality using the D'Agostino-Pearson normality test. Differences in drooling, gingivitis, ulcers, stomatitis, laryngitis, tartar, dental caries, abscess, and lingual lesions before (T0) and at the end of the evaluation period (T1) were analyzed using a Mann-Whitney test. A value for $*p < 0.05$ was considered significant.

RESULTS

One hundred four dogs suffering from chronic halitosis and manifesting at least one symptom among drooling, gingivitis, ulcers, stomatitis, laryngitis, tartar, dental caries, abscess, and lingual lesions were enrolled in this evaluation, and received a commercially available nutraceutical diet for 30 days. No adverse effects were reported during the evaluation. In Figure 1, the score trend of each symptom, before (T0) and at the end of the evaluation period (T1), are shown.

Halitosis significantly decreased from a T0 score of 2.11 ± 0.08 to 0.43 ± 0.07 at T1 ($***p < 0.001$). Also drooling resulted significantly decreased from a T0 score of 1.31 ± 0.04 to 0.61 ± 0.09 at T1 ($***p < 0.001$). A similar trend was observed also for gingivitis, ulcers, stomatitis, laryngitis, dental caries, abscesses, and lingual lesions. In particular:

- gingivitis significantly decreased from a T0 score of 2.17 ± 0.05 to 0.62 ± 0.04 at T1 ($***p < 0.001$)
- ulcers significantly decreased from a T0 score of 1.98 ± 0.01 to 0.08 ± 0.02 at T1 ($***p < 0.001$)
- stomatitis significantly decreased from a T0 score of 1.01 ± 0.01 to 0.33 ± 0.04 at T1 ($***p < 0.001$)
- laryngitis significantly decreased from a T0 score of 1.02 ± 0.01 to 0.03 ± 0.01

at T1 (**p < 0.001)

- dental caries significantly decreased from a T0 score of 2.9 ± 0.02 to 0.07 ± 0.02 at T1 (**p < 0.001)
- abscesses significantly decreased from a T0 score of 1.04 ± 0.02 to 0.08 ± 0.02 at T1 (**p < 0.001), and
- lingual lesions significantly decreased from a T0 score of 1.94 ± 0.02 to 0.14 ± 0.03 at T1 (**p < 0.001).

DISCUSSION

We found that a nutraceutical based on *Ribes nigrum*, *Salvia officinalis* L, *Thymus* L, egg white lysozyme, propolis, bioflavonoids, and vitamin C significantly improved halitosis and related symptoms in a cohort of dogs. These results are in agreement to what we previously observed in dogs affected by chronic halitosis achieving an overall and long-lasting improvement due to a significant reduction of methyl mercaptan, hydrogen sulfide, and dimethyl sulfide.²⁰

Canine halitosis, a very common complaint for pet owners, is known to have different origins such as gastrointestinal disorders, renal failure, and respiratory infections.^{2,3} Along with gingivitis, ulcers, stomatitis, laryngitis, abscess, and lingual lesions, halitosis shares an overall inflammatory condition that can also be a consequence of a daily intake of contaminated food.^{21,22} In fact, we recently identified the presence of an antibiotic (oxytetracycline), widely used in the intensive farming²³ that tends to bind bone of treated animals remaining fixed for long periods, causing inflammatory and cytotoxic phenomena *in vitro* (24-27) and *in vivo*.^{21,22,28} Moreover, the bone percentage employed in pet food production ranges between 20-30% v/v. In light of these observations, we hypothesize a role for oxytetracycline as a possible cause of the inflammatory condition that characterizes halitosis, and that a diet deprived of such antibiotic may represent a valuable alternative to counteract such unpleasant condition.

Statement of Authorship

The authors hereby certify that all work con-

tained in this article is original. The authors claim full responsibility for the contents of the article.

Conflict of Interest

The authors confirm that they do not have any conflict of interest

REFERENCES

1. Iwanicka-Grzegorek E, Kepa J, Lipkowska E, Michalik J, Pierzynowska E, Placha R. Is transmission of bacteria that cause halitosis from pets to humans possible? *Oral Dis.* 2005;11 Suppl 1:96-7.
2. Culham N, Rawlings JM. Oral malodor and its relevance to periodontal disease in the dog. *J Vet Dent.* 1998;15(4):165-8.
3. Hennet PR, Delille B, Davot JL. Oral malodor measurements on a tooth surface of dogs with gingivitis. *Am J Vet Res.* 1998;59(3):255-7.
4. Simone AJ, Logan EI, Livgren R, Suelzer M. Oral malodor in beagles: association with indicators of periodontal disease. *J Clin Dent.* 1997;8(6):163-8.
5. Tromp JA, Jansen J, Pilot T. Gingival health and frequency of tooth brushing in the beagle dog model. Clinical findings. *J Clin Periodontol.* 1986;13(2):164-8.
6. Association AAH. The Path to High Quality Care: Practical Tips for Improving Compliance: American Animal Hospital Association; 2003.
7. Quest BW. Oral health benefits of a daily dental chew in dogs. *J Vet Dent.* 2013;30(2):84-7.
8. Jeusette IC, Roman AM, Torre C, Crusafont J, Sanchez N, Sanchez MC, et al. 24-hour evaluation of dental plaque bacteria and halitosis after consumption of a single placebo or dental treat by dogs. *Am J Vet Res.* 2016;77(6):613-9.
9. Lindinger MI. Reduced Dental Plaque Formation in Dogs Drinking a Solution Containing Natural Antimicrobial Herbal Enzymes and Organic Matcha Green Tea. *Scientifica* (Cairo). 2016;2016:2183623.
10. Low SB, Peak RM, Smithson CW, Perrone J, Gaddis B, Kontogiorgos E. Evaluation of a topical gel containing a novel combination of essential oils and antioxidants for reducing oral malodor in dogs. *Am J Vet Res.* 2014;75(7):653-7.
11. Widen C, Renvert S, Persson GR. Antibacterial activity of berry juices, an *in vitro* study. *Acta Odontol Scand.* 2015;73(7):539-43.
12. Ikuta K, Hashimoto K, Kaneko H, Mori S, Ohashi K, Suzutani T. Anti-viral and anti-bacterial activities of an extract of blackcurrants (*Ribes nigrum* L.). *Microbiol Immunol.* 2012;56(12):805-9.
13. Sterer N, Nuas S, Mizrahi B, Goldenberg C, Weiss EI, Domb A, et al. Oral malodor reduction by a palatal mucoadhesive tablet containing herbal formulation. *J Dent.* 2008;36(7):535-9.
14. Linka WA, Golenia E, Zgoda MM, Kolodziejczyk MK. [The use of semi-synthetic polymers in the formulation of sucking and chewable tablets containing sage extract and zinc gluconate]. *Polim Med.* 2014;44(4):237-45.

15. Ghorbani A, Esmaeilizadeh M. Pharmacological properties of *Salvia officinalis* and its components. *J Tradit Complement Med.* 2017;7(4):433-40.
16. Sterer N, Rubinstein Y. Effect of various natural medicinals on salivary protein putrefaction and malodor production. *Quintessence Int.* 2006;37(8):653-8.
17. Chatterjee A, Saluja M, Agarwal G, Alam M. Green tea: A boon for periodontal and general health. *J Indian Soc Periodontol.* 2012;16(2):161-7.
18. Yumnam R, N N, C KN, Raj S, Mannepalli A. EFFECT OF PROPOLIS IN ORAL HEALTH. *Journal of Ayurveda and Integrated Medical Sciences* (ISSN 2456-3110). 2017(1):186-92%V 2.
19. Kilkenny C, Browne WJ, Cuthill IC, Emerson M, Altman DG. Improving bioscience research reporting: the ARRIVE guidelines for reporting animal research. *Osteoarthritis Cartilage.* 2012;20(4):256-60.
20. Di Cerbo A, Pezzuto F, Canello S, Guidetti G, Palmieri B. Therapeutic Effectiveness of a Dietary Supplement for Management of Halitosis in Dogs. *J Vis Exp.* 2015(101):e52717.
21. Di Cerbo A, Canello S, Guidetti G, Fiore F, Corsi L, Rubattu N, et al. Adverse food reactions in dogs due to antibiotic residues in pet food: a preliminary study. *Vet Ital.* 2018.
22. Mazzeranghi F, Zanotti C, Di Cerbo A, Verstegen JP, Cocco R, Guidetti G, et al. Clinical efficacy of nutraceutical diet for cats with clinical signs of cutaneous adverse food reaction (CAFR). *Pol J Vet Sci.* 2017;20(2):269-76.
23. Palmieri B, Di Cerbo A, Laurino C. Antibiotic treatments in zootechnology and effects induced on the food chain of domestic species and, comparatively, the human specie. *Nutr Hosp.* 2014;29(6):1427-33.
24. Di Cerbo A, Palatucci AT, Rubino V, Centenaro S, Giovazzino A, Fraccaroli E, et al. Toxicological Implications and Inflammatory Response in Human Lymphocytes Challenged with Oxytetracycline. *J Biochem Mol Toxicol.* 2016;30(4):170-7.
25. Odore R, De Marco M, Gasco L, Rotolo L, Meucci V, Palatucci AT, et al. Cytotoxic effects of oxytetracycline residues in the bones of broiler chickens following therapeutic oral administration of a water formulation. *Poult Sci.* 2015;94(8):1979-85.
26. Di Cerbo A, Rubino V, Morelli F, Ruggiero G, Landi R, Guidetti G, et al. Mechanical phenotyping of K562 cells by the Micropipette Aspiration Technique allows identifying mechanical changes induced by drugs. *Sci Rep.* 2018;8(1):1219.
27. Gallo A, Landi R, Rubino V, Di Cerbo A, Giovazzino A, Palatucci AT, et al. Oxytetracycline induces DNA damage and epigenetic changes: a possible risk for human and animal health? *PeerJ.* 2017;5:e3236.
28. Di Cerbo A, Canello S, Guidetti G, Laurino C, Palmieri B. Unusual antibiotic presence in gym trained subjects with food intolerance; a case report. *Nutr Hosp.* 2014;30(2):395-8.