

A Case of Intersexuality in a Pig: Histological View

Pavol Makovicky^{1*}

Alexander V. Sirotkin²

Peter Makovicky³

¹Department of Biology, Faculty of Education, J. Selye University, Bratislavská 3322, 945 01 Komarno, Slovak Republic. E-mail: makovicky.pavol@gmail.com

²Department of Zoology and Anthropology, Faculty of Natural Sciences, Constantine the Philosopher University, Tr. A. Hlinku 1, 949 74 Nitra, Slovak Republic.

³Czech Centre for Phenogenomics, Division BIOCEV, Prumyslova 595, 252 50 Vestec, Czech Republic.

KEY WORDS: Ovary, reproduction, swine, testes

ABSTRACT

Intersexual individuals have both female and male genital tissues. We have described a case of an intersexual pig, which was identified during veterinary inspection of pigs at slaughterhouse. This organ represented ovotestis. Half of its tissues was represented by ovarian tissue resembling ovary by polycystic ovary syndrome. Another half was represented by testicular tissue with signs of germ cell aplasia. These observations can contribute to understanding the expression of intersexuality and intersexuality-reduced infertility in pigs, whose should be withdrawn from commercial and reproductive breeds. The careful analysis of reproductive organs of pigs with veterinarian diagnosis “intersexuality” by various methods is recommended.

INTRODUCTION

Sexual disorders are important due to their influence on reproduction and other physiological processes regulated by gonadal hormones. One of such disorder can be hermaphroditism (presence of both male and female gonads), pseudohermaphrodit-

ism (development of gonads of an opposite sex), and intersexuality (combination of testicular and ovarian tissues in one gonad).¹ Incidence of intersexuality in pigs has been reported by various authors.^{2,3} The incidence of intersexuality associated with infertility in domestic pig population was counted as 0,48 % (Australia),⁴ 0,5% (Korea),⁵ or 0,75% (France).⁶

The most common form of intersexuality in pigs is female masculinization.⁷ Such intersexuality can be associated with infertility, occurrence of aggressive behaviour, and bad smell of the meat products induced by androgens produced by testicular tissue.⁸ The incidence of this disorder is explained by genetic factors, chromosomal anomalies, or hormonal imbalance during embryogenesis, but the mechanisms of development and function of intersexual organs remains to be established. Intersexuality in pigs has been usually detected on the basis of anatomical and macroscopic inspection of sexual organs.⁹ Little is known about microstructure of intersexual organs, functions, and interrelationships between their male and female components and their possible pathological transformations resulting in infertility.

This case report describes the results of histological analysis of the generative organ of the intersexual pig, which was identified during veterinary inspection of pigs slaughtered at local slaughterhouse. Such analysis was done to understand the presence and state of its possible male and female components, and to examine their generative, secretory, and proliferative activities.

MATERIAL AND METHODS

Source and Description of the Collected Organ

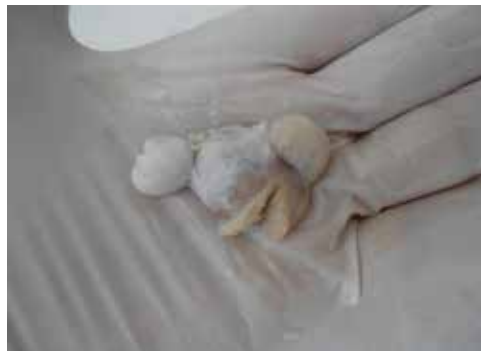The described organ was collected during slaughtering of 100-120 kg pubertal gilts of various breeds at the slaughterhouse in Czech Republic. It was sent to a histopathological laboratory for histological analysis and subsequent diagnosis. This organ was located in the end of horn of uterus, at the place of the ovary. It looked as a 2x1,5x1 cm, compact yellow ovary with several small follicles at its surface, surrounded by two 1x0,5x0,5 cm compact white-yellow formations looked as testes (Figure 1).

Samples Processing and Evaluation

The collected formation was subjected to histological analysis. Briefly, both parts of the delivered material (resembling ovary and testes) were processed using a Leica ASP6025 automatic vacuum tissue processor (Leica Biosystems Nussloch GmbH, Heidelberg, Germany). The samples were embedded in paraffin blocks using a Leica EG 1150H embedding station (Leica Biosystems Nussloch GmbH, Heidelberg, Germany). The samples were further cut on a Leica RM2255 rotary microtome (Leica Biosystems Nussloch GmbH, Heidelberg, Germany).

Sections were placed on special silanized slides (Thermo Scientific, Superfrost® Plus, Braunschweig, Germany) and stained with haematoxylin-eosin to view their histomorphology (Bamed, s.r.o., České Budějovice, Czech republic) using a Leica ST5020 staining machine (Leica Biosystems Nussloch GmbH, Heidelberg, Germany). Other series of cuts were stained by Bench

Figure 1. The view to the delivered material.



Mark Special Stains (Roche Diagnostics GmbH, Mannheim, Germany) for detection of polysaccharides with PAS Staining Kit Ventana® (Ventana medical System, Inc., Tuscon, Arizona, USA) and for the verification of collagen with Trichrome Staining Kit Ventana® (Ventana medical System, Inc., Tuscon, Arizona, USA). The last slices were stained with immunohistochemistry with Ki-67 to detect cell proliferation (Lindboe and Torp, 2002).

Before immunostaining, heat-induced antigen retrieval was performed by 20 min. treatment in AVAIR IDA pressure cooker (FSQEA, Ltd., Foshan City, China) using HIER Citrate Buffer pH6 (Zytomed Systems GmbH, Berlin, Germany). After this using Discovery Stainer (Ventana medical System, Inc., Tuscon, Arizona, USA) the slices were stained with Ki-67 Antibody (SP6) antibody (Thermo Fischer Scientific, Waltham, MA USA). Reaction was visualized with DAB Substrate Buffer (Zytomed Systems GmbH, Berlin, Germany). Finally slices were counterstained with Mayer haematoxylin. All the samples were inspected and evaluated at a light microscopic image obtained using Carl Zeiss Scope.A1 microscope (Zeiss, Munchen, Germany).

Statistics

Each second prepared slice was stained by hematoxylin-eosin, for PAS, for Masson trichrome and for Ki-67. In total, four slices were stained and analyzed.

RESULTS

Histological analysis reveals that the organ

contained two distinct parts – ovarian and testicular tissues represented in equal proportions. The ovarian compartment contained several groups of primary ovarian follicles localized in cortical part of the tissue. Some of these primary follicles contained oocytes with swollen and disintegrated nuclei. The major population of ovarian follicles was, however, represented by growing secondary and antral follicles without visible oocytes in the antrum folliculi. The deformations and thickening of follicular wall with partially degenerated zona granulosa, theca interna and theca externa.

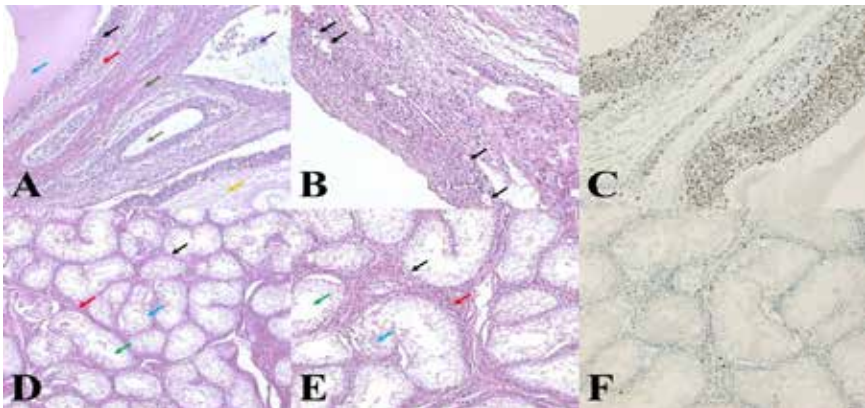
The stromal part of the ovarian compartment was represented by good vascularized fat-between sparse stromal serosa cells. The intracellular spaces and follicular fluid contained PAS-positive material. Immunocytochemistry revealed a number of proliferating

(Ki-67-positive) granulosa and stromal cells (Figure 2 A, B, C). The testicular part of the organ contained well-recognized tubular structures bordered with one layer of epithelial cells looking like Sertoli cells with a number of semi vital or necrotic elements. Testicular lumen was filled with serosa PAS-positive secret and cellular detritus. Stromal cells were connected with collagen membrane. It was represented by oval eosinophilic cells with basophilic eccentric nuclei resembling Leydig cells. Only small number of stromal cells and no cell within the testicular channel were proliferating (KI-67-positive) (Figure 2 D, E, F).

DISCUSSION

The intersexuality in each species is detectable utilizing macroscopic, histological, endocrine, cytogenetic, and genetic markers.

Figure 2. A: Ovarian part of ovotestis: growing follicles with comprised (black arrow), or disintegrated (purple arrow) membrana granulosa and into the contact fibrous tissue (red arrow) resembling thecal tissue and fibrous tissue. All the follicles are without oocytes with pinkish (blue arrow), sparse pinkish (yellow arrow) or only serous secret (grey arrow) into the lumen. Legend: Haematoxylin-eosin staining, x 100. **B:** Detail of ovarian part of ovotestis: primary follicles with centrally localised ballooned oocytes. Legend: Haematoxylin-eosin staining, x 200. **C:** Detail of ovarian part of ovotestis: intensive proliferation activity of granulosa cells and ovarian stromal cells. Legend: Ki-67, x 200. **D:** Testicular part with several tubular formations, which are lined by simple-layered epithelium (black arrow) with some serous secret (blue arrow) and empty lumen (green arrow). Mass of Leydig cells into the interstitial tissue are visible (red arrow). Legend: Haematoxylin-eosin staining, x 100. **E:** Detail of testicular part of ovotestis: several tubular formations, which are lined by simple-layered epithelium (black arrow) with some serous secret (blue arrow) and empty lumen (green arrow). Numerous Leydig cells into the interstitial tissue (red arrow). Legend: Haematoxylin-eosin staining, x 200. **F:** Detail of testicular part of of ovotestis: only few proliferating stromal cells, practically no proliferating cells in seminiferous tubules. Legend: Ki-67, x 200.



Sometimes these markers can be inductors of intersexuality and related infertility, and sometimes they are useful for diagnostics and even treatment of intersexuality related reproductive disorders. It is known that in pigs, two major types of disorders of sexual development are observed. The first one is testicular or ovotesticular disorder, with female sex chromosome complement (XX) and lack of SRY gene. The second one is freemartinism, manifested by XX/XY chimerism in leukocytes.

For an appropriate classification of these cases the description of external and internal genitalia, sex chromosome analysis, SRY gene detection, analysis of testosterone, and estradiol levels in blood and histology of gonads are suggested. Our study is concentrated on ovotestis histology analysis. The outlook and position of the organ can be useful indexes to determine character of gonadal transformation. Sometimes intersexuality is associated with abnormality of visible genitalia. If the male gonads are dominating, the appearance of ovarian tissue in the testis can induce testicular malformation (small undeveloped testis). The presence of testicular tissue in dominating ovarian compartment results occurrence of ovotestis near the horn of uterus, sometimes with testicular elements which can be identified by naked eye.¹⁰ The position of the organ described in this paper near the end of this horn corresponds with this form of intersexuality and suggests that it represents ovotestis with developed ovarian compartment.

The results of histological analysis of this organ supported this hypothesis. It contained both ovarian and testicular compartments. The degenerative changes in testicular compartment had signs of hyperplasia and germ cell aplasia (Sertoli cell syndrome, which is characterized by presence of Sertoli cells, but not of Leydig or spermatogenic cells), whose are characteristics of ovotestis.¹¹ On the other hand, the numerous growing follicles with thin granulosa layer and absence of large antral follicles resembles

ovarian structures observed during polycystic ovarian (Stein Leventhal) syndrome.¹² The absence of functional generative cells both in testicular and ovarian parts are signs of intersex-induced infertility. On the other hand, the occurrence of endocrine parts of both testicular and ovarian compartments and the proliferation of endocrine cells in the ovarian compartment suggest that the endocrine part of ovotestis is active.

The endocrine activity could be a cause of morphological and generative abnormalities observed in intersex gonads. For example, the characteristics and possible cause of polycystic ovarian syndrome can be hyper-production of testosterone, which in turn can be due to hypersecretion of luteinizing hormone (LH) and secretion of follicle stimulating hormone (FSH).¹³ On the other hand, hormones produced by testicular Leydig cells can inhibit the differentiation and development of the female gonads and induce masculinisation of pigs with all its consequences.¹⁴ Therefore, the blood level of reproductive hormones could be the next useful index of intersexual state, which we could recommend to use in daily veterinary praxis.

The endocrine and subsequent morphological and physiological characteristics and malformation are regulated by particular genes. There is evidence that the development of ovotestis is a consequence of chromosomal aberrations in animal karyotype.¹⁵ Sexual differentiation and development are regulated by several genes located in both X and Y chromosomes and in autosomes. The involvement and interplay of genes like Wnt4,^{16,17} Rspo1,¹⁸ beta-katenin,¹⁹ SOX9, FGF9,²⁰ FOXL2 and SMAD4,²¹ in control of gonadal differentiation and release of its hormonal regulator FSH has been demonstrated. It is proposed that appearance of intersexual pigs can be due to autosomal recessive gene, which is transferred by boars. These boars are to be excluded from reproduction.²²

Therefore, both the cytogenetic and genetic analysis can be the next tool to detect

intersexuality, to understand its causes, and to improve animal breeding. Such analysis would be desirable in veterinary praxis. These analyses are time- and money-consuming, but they, together with macro and microscopic analysis, can provide new information in such rare causes as intersexuality and to eliminate them from pig population.

ACKNOWLEDGEMENTS

J. Selye University management is gratefully thanked for the costs associated with the publication of this article. To Slovak Research and Development Agency (APVV) (project APVV-15-0296), as well as to the Slovak Grant Agency of the Ministry of Education, Science, and Sport, the Slovak Academy of Science (VEGA) (project VEGA 1/0392/17) for support of this study.

STATEMENT OF AUTHORSHIP

The authors hereby certify that all work contained in this article is original. The authors claim full responsibility for the contents of the article.

CONFLICT OF INTEREST

The authors confirm that they do not have any conflict of interest.

REFERENCES

- Maxie G. Jubb, Kenedy, and Palmers Pathology of domestic animals. *Elsevier*. 2016;798.
- Switonski M, Jackowiak H, Godynicki S, Klukowska J, Borsiak K, Urbaniak K. Familial occurrence of pig intersexes (38,XX;SRY-negative) on a commercial fattening farm. *Anim Reprod Sci*. 2002;69(1-2):117-124.
- Rousseau S, Iannuccelli N, Mercat MJ, Naylies C, Thouly JC, Servin B, Milan D, Pailhoux E, Riquet J. A genome-wide association study points out the causal implication of SOX9 in the sex-reversal phenotype in XX pigs. *PLoS One*. 2013;11:e79882.
- Pfeffer A, Winter H. Hermaphrodites in Australian pigs. Occurrence and morphology in an abattoir survey. *Aust Vet J*. 1997;53(4):153-162.
- Lee DS, Lee JH, Park JY, Lee SJ, Kim KJ, Kim EY, Son SH, Woo JS, Kim MK. Histological and genetic characterisation of true hermaphroditism in Korean pigs. *J Vet Med Sci*. 2013;75(2):203-206.
- Pailhoux E, Popescu PC, Parma P, Boscher J, Legault C, Molteni L, Fellous M, Cotinot C. Genetic analysis of 38XX males with genital ambiguities and true hermaphrodites in pigs. *Anim Genet*. 1994;25(5):299-305.
- Bansal N, Roy KS, Sharma DK, Sharma R. Anatomical study on true hermaphroditism in an Indian pig (*Sus scrofa domestica*). *J Vet Sci*. 2005;6(1):83-85.
- Howard PE, Bjorling DE. The intersexual animal. Associated problems. *Probl Vet Med*. 1989;1(1):74-84.
- Gopinathan A, Ramesh J, Jaishankar S, Palanivel N, Senthil-Kumar S, Sivakumar T. True hermaphroditism in a large White Yorkshire pig – Case report. *Res Rev J Vet Sci*. 2015;1(1):1-4.
- Tiranti IN, Genghini RN, Quintana HG, Wittouck P. Morphological and karyotypic characterization of intersex pigs with hernia inguinalis. *J Agr Sci*. 2002;138(3):330-340.
- Nelson WO. Testicular biopsy. In: Tyler et al.: Sterility – office management of the infertile couple. New York. 1961.
- Azziz E, Carmina E, Chen Z, Dunaif A, Laven JS, Largo RS, Lizneva D, Natterson-Horowitz B, Teede HJ, Yildiz BO. Polycystic ovary syndrome. *Nat rev Dis Primers*. 2016;2(16057):57.
- Faubert J, Battista MC, Baillageon JP. Physiology and endocrinology symposium: Insulin action and lipotoxicity in the development of polycystic ovary syndrome: A review. *J Anim Sci*. 2016;94(5):1803-1811.
- Pailhoux E, Mandon-Pepin B, Cotinot C. Mammalian gonadal differentiation: the pig model. *Reprod Suppl*. 2001;58(1):65-80.
- Villagómez DA, Parma P, Radi O, Di Meo G, Pinton A, Iannuzzi L, King WA. Classical and molecular cytogenetics of disorders of sex development in domestic animals. *Cytogenet Genome Res*. 2009;126(1-2):110-131.
- Biason-Lauber A, Chaboissier MC. Ovarian development and disease: The known and the unexpected. *Semin Cell Dev Biol*. 2015;45(9):59-67.
- Pellegrino M, Maiorino R, Schonauer S. WNT4 signaling in female gonadal development. *Endocr Metab Immune Disord Drug Targets*. 2010;10(2):168-174.
- Chassot AA, Gillot I, Chaboissier MC. R-spondin1, WNT4, and the CTNBN1 signaling pathway: strict control over ovarian differentiation. *Reproduction*. 2014;148(6):R97-R110.
- Liu CF, Parker K, Yao HH. WNT4/beta-catenin pathway maintains female germ cell survival by inhibiting activin betaB in the mouse fetal ovary. *PLoS One*. 2010;4:e10382.
- Uhlenhaut NH, Treier M, Foxl2 function in ovarian development. *Mol Genet Metab*. 2006;88(3):225-234.
- Li Y, Schang G, Wang Y, Zhou X, Levasseur A, Boyer A, Deng CX, Treier M, Boehm U, Boerboom D, Bernard DJ. Conditional deletion of FOXL2 and SMAD4 in gonadotropes of adult mice causes isolated FSH deficiency. *Endocrinology*. 2018;159(7):2641-2655.
- Hunter RH, Greve T. Intersexuality in pigs: clinical, physiological and practical considerations. *Acta Vet Scand*. 1996;37(1):1-12.